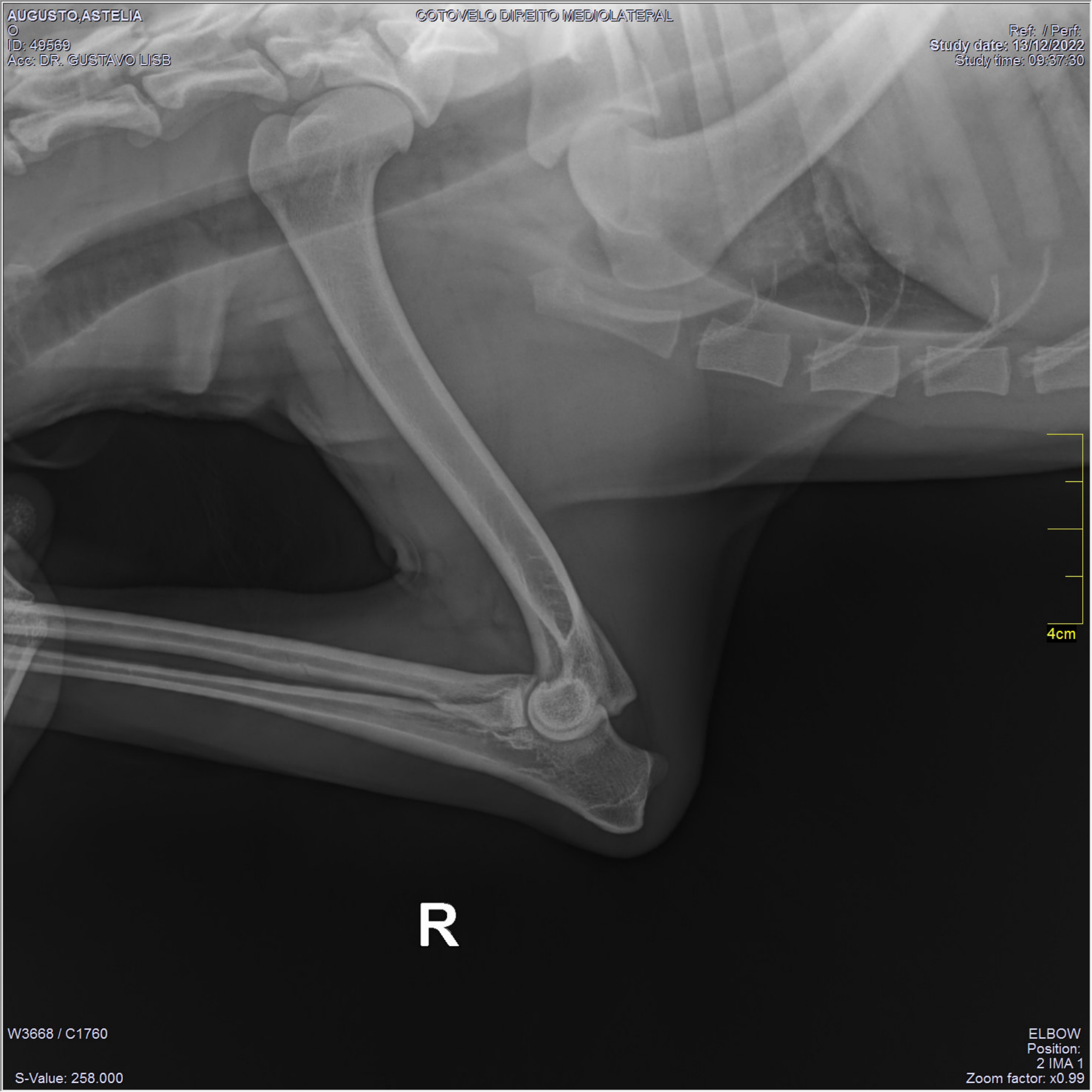
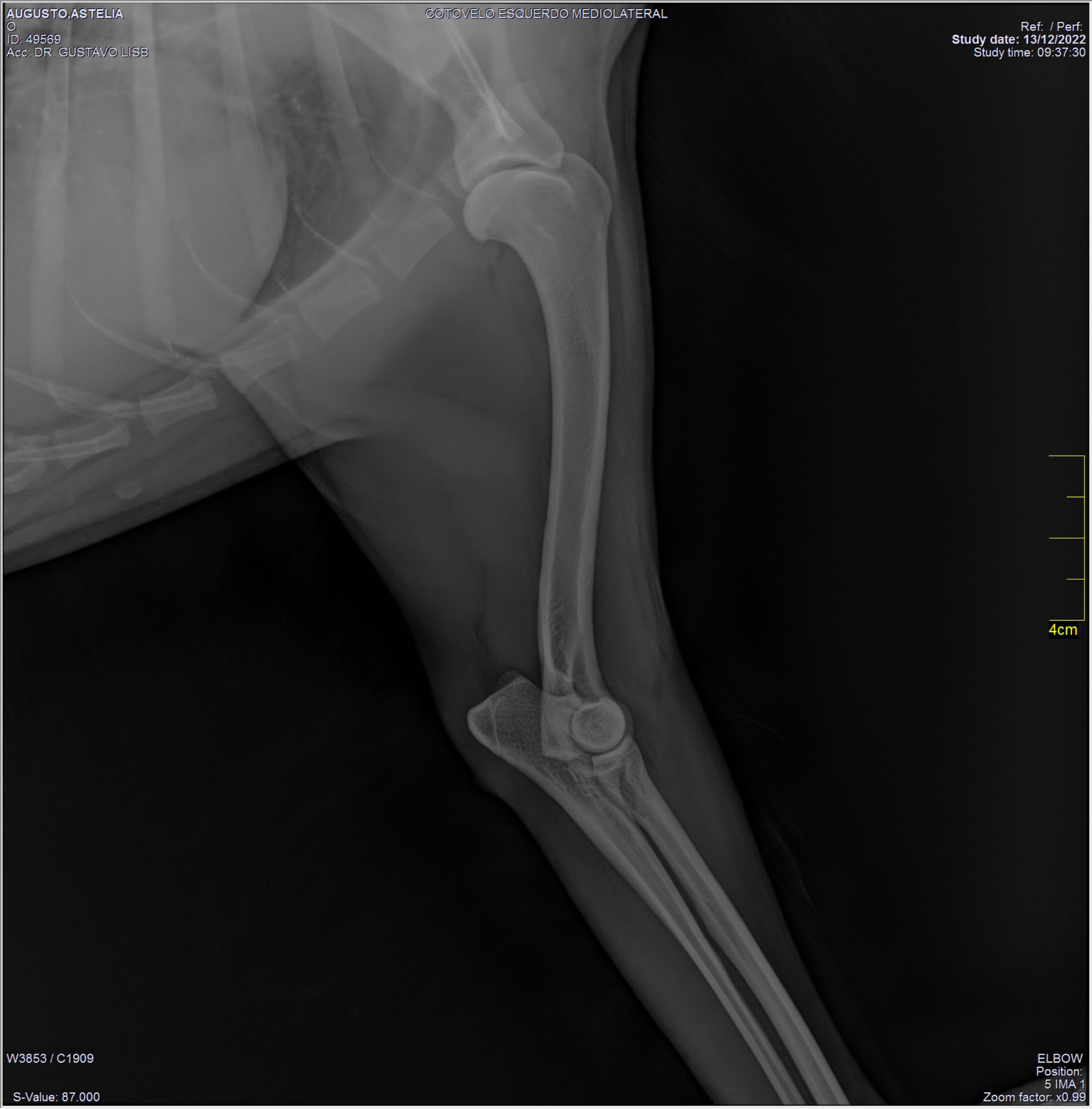


R

4cm



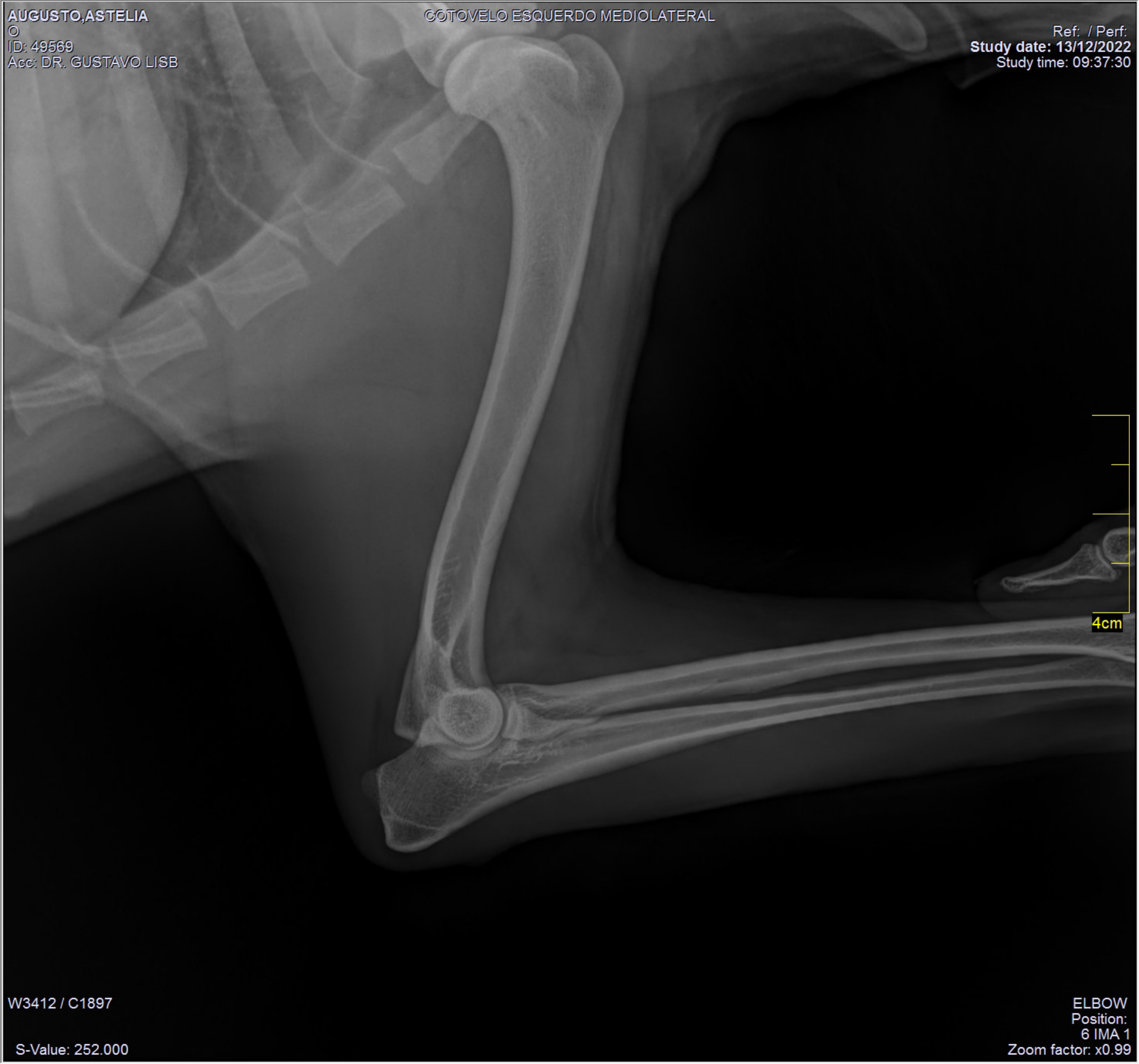
R



AUGUSTO, ASTELIA  
ID: 49569  
Acc: DR. GUSTAVO LISB

COTOVELO ESQUERDO MEDIOLATERAL

Ref: / Perf:  
Study date: 13/12/2022  
Study time: 09:37:30

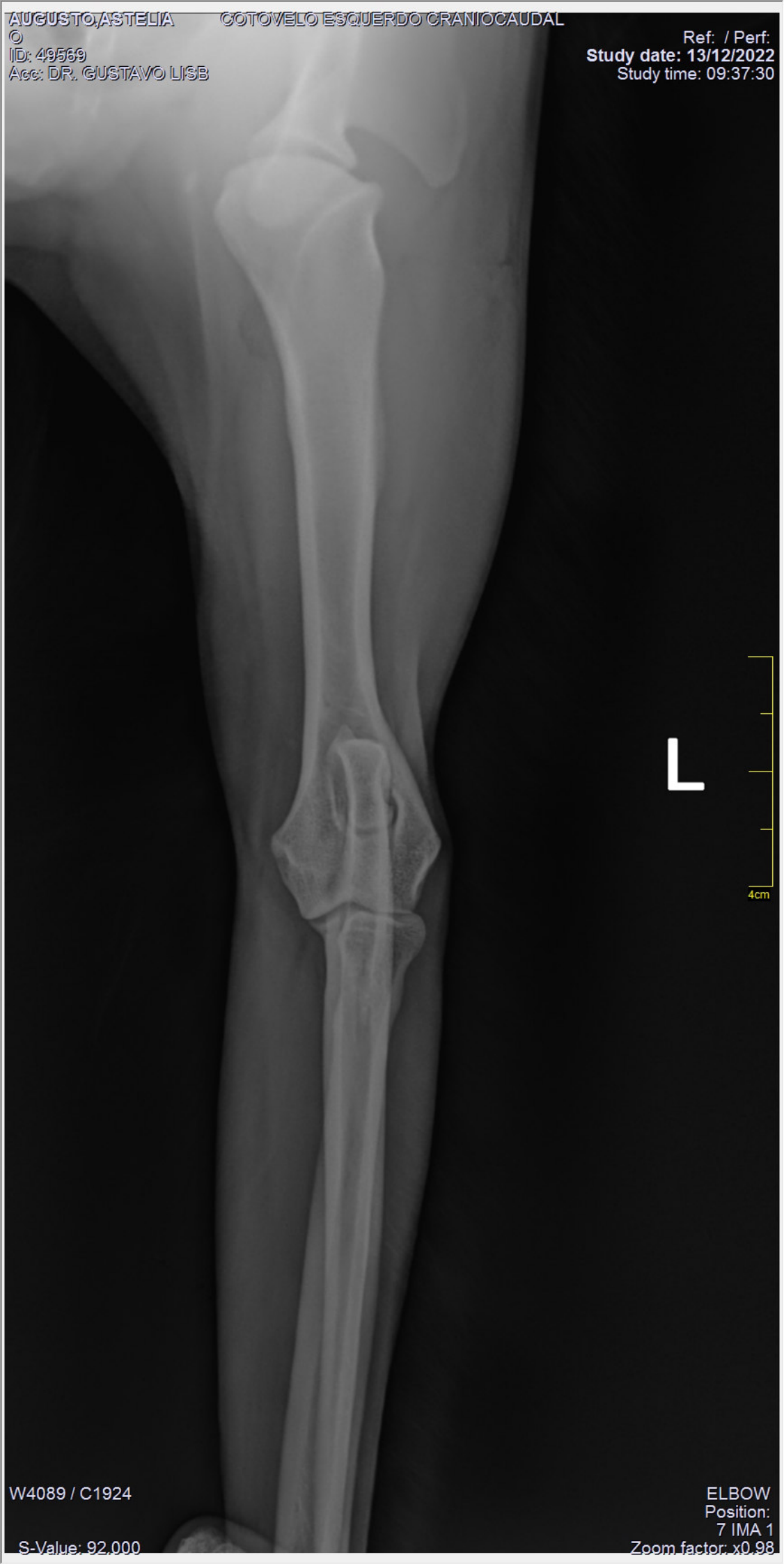


4cm

W3412 / C1897

S-Value: 252.000

ELBOW  
Position:  
6 IMA 1  
Zoom factor: x0.99



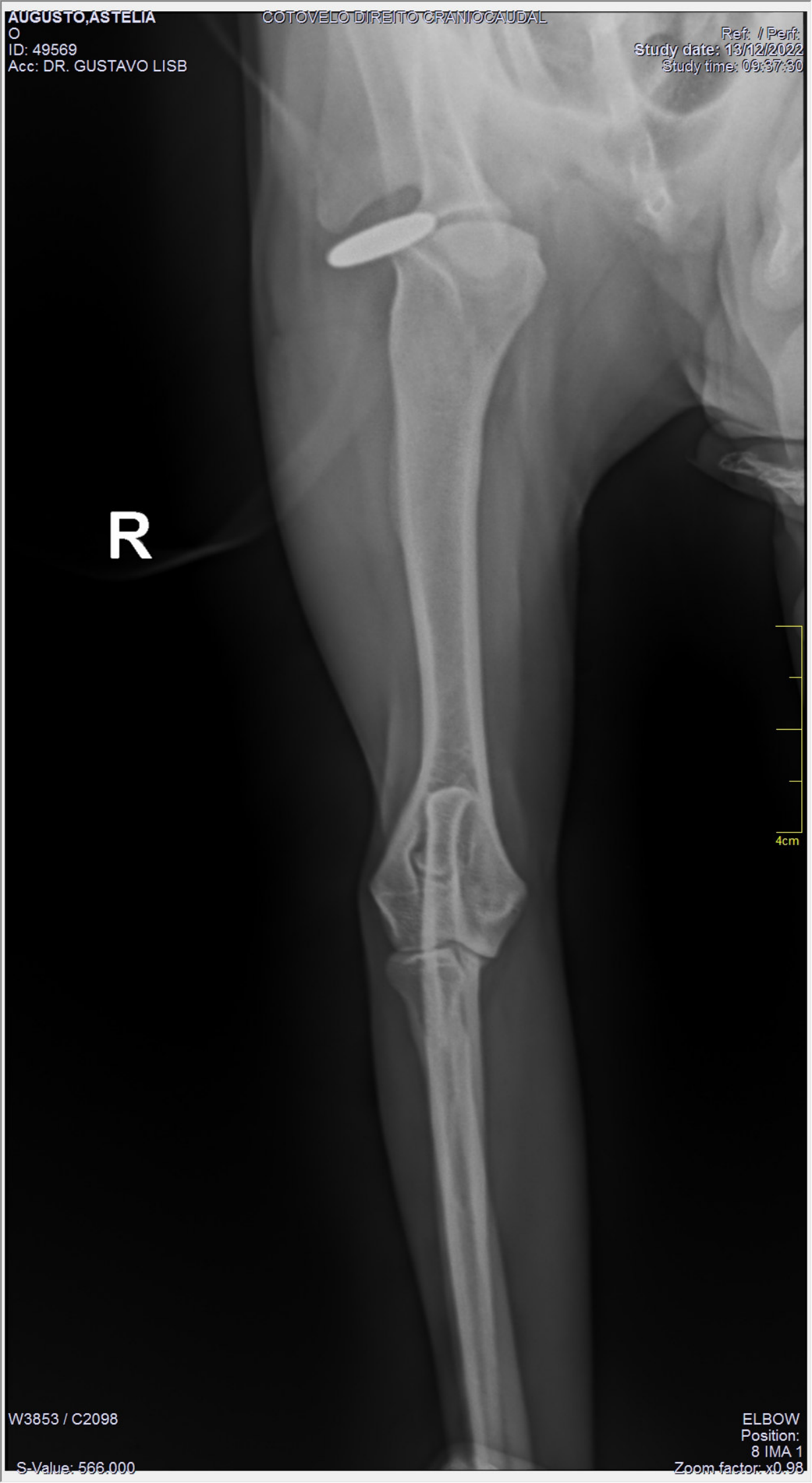
L

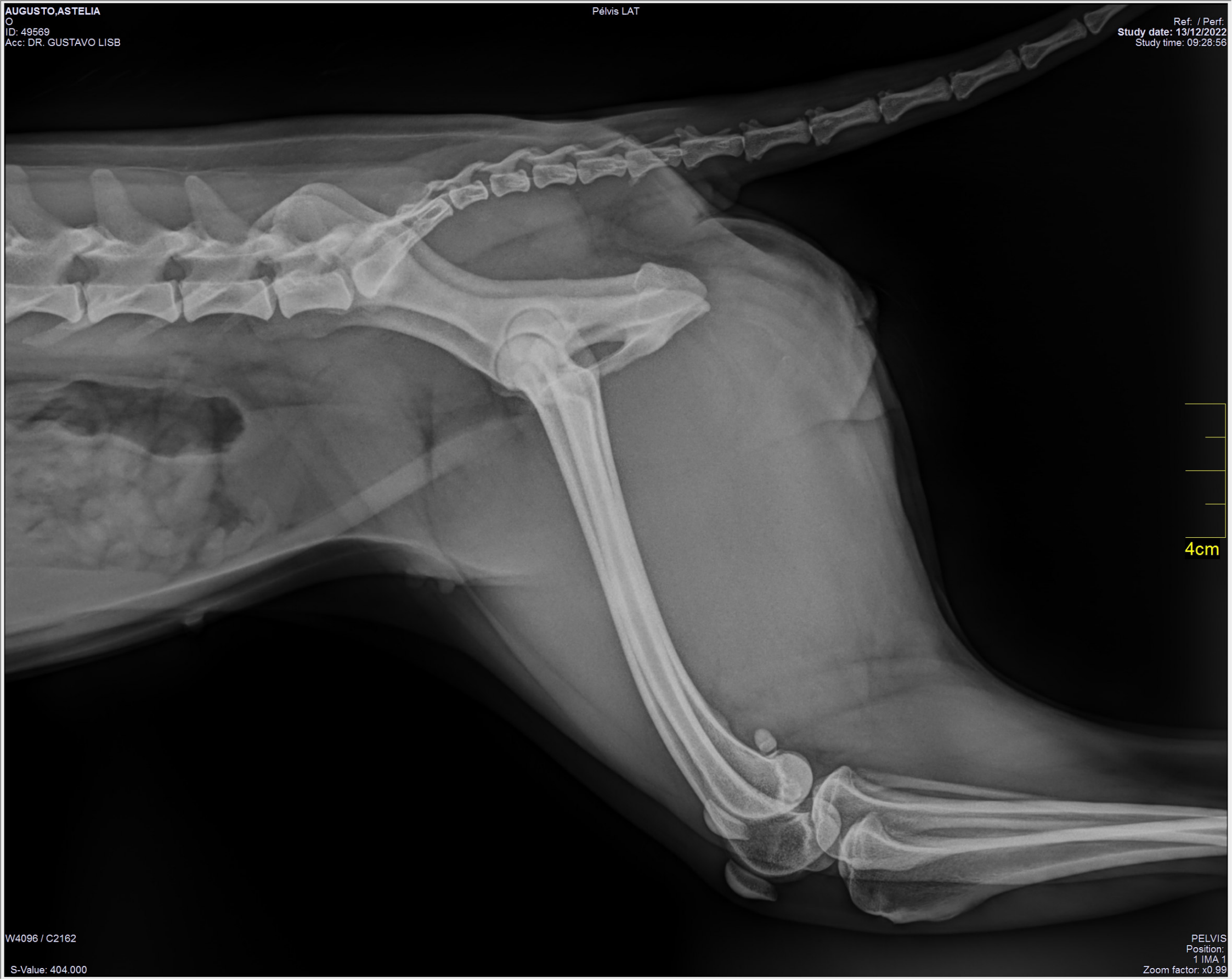


4cm

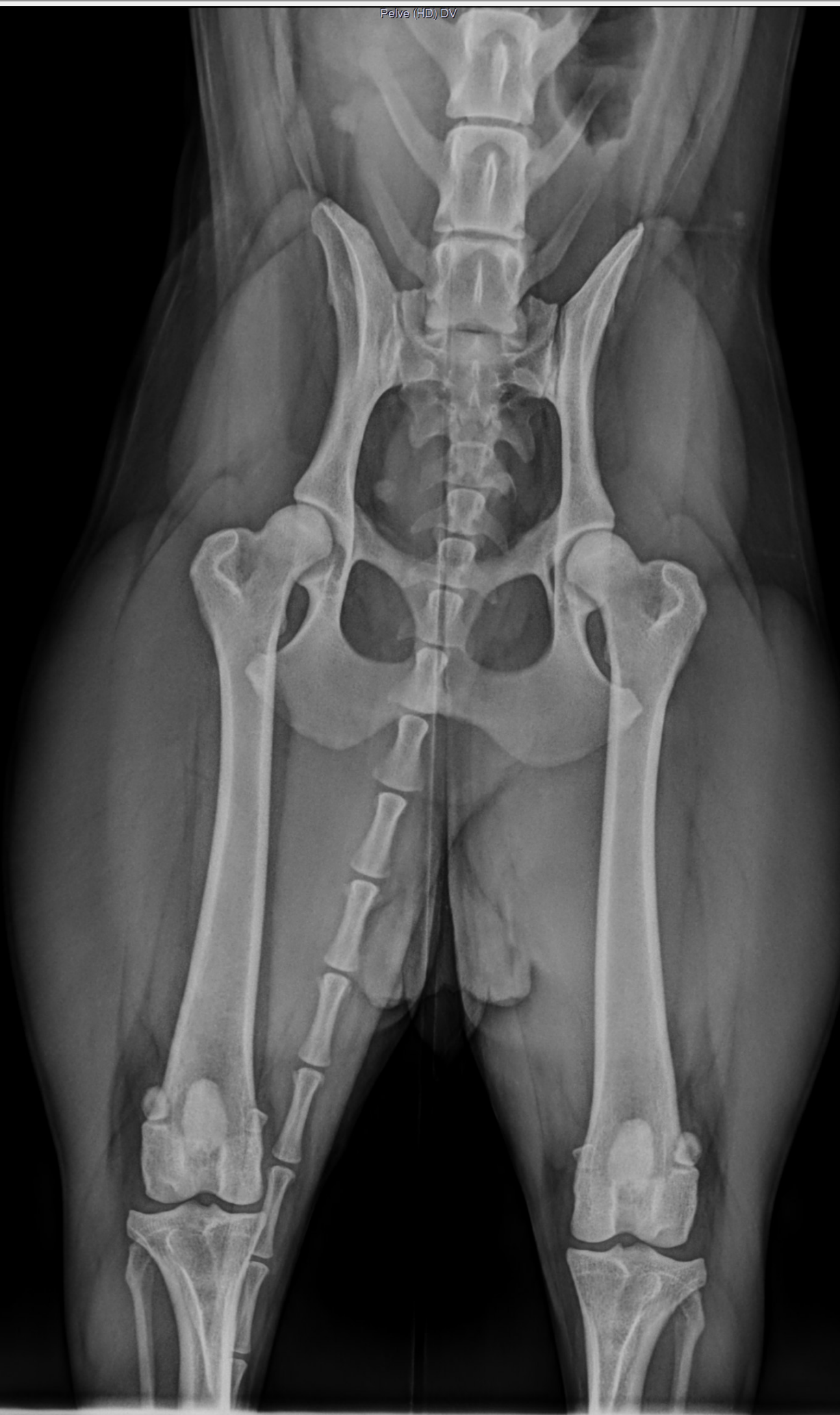
R

4cm





DIREITO



O/A: AUGUSTO, ASTELIA

ID: 49569

DOB: ---

Examination: Vertebrae / Pelvis

date/time: 13/12/2022 / 09:28

Physician: ---

life number: